

# HEART DISEASE

## Normal Heart

Superior vena cava  
Right atrium  
Aortic valve  
Tricuspid valve  
Hypertrophic (thickened) myocardium  
Chordae tendineae  
Aortic arch  
Main pulmonary trunk  
Left atrium  
Mitral valve  
Chordae tendineae  
Left ventricle  
Interventricular septum  
Right ventricle

## Congestive Heart Failure

Enlarged heart characteristic of CHF

Hypertrophic (thickened) myocardium

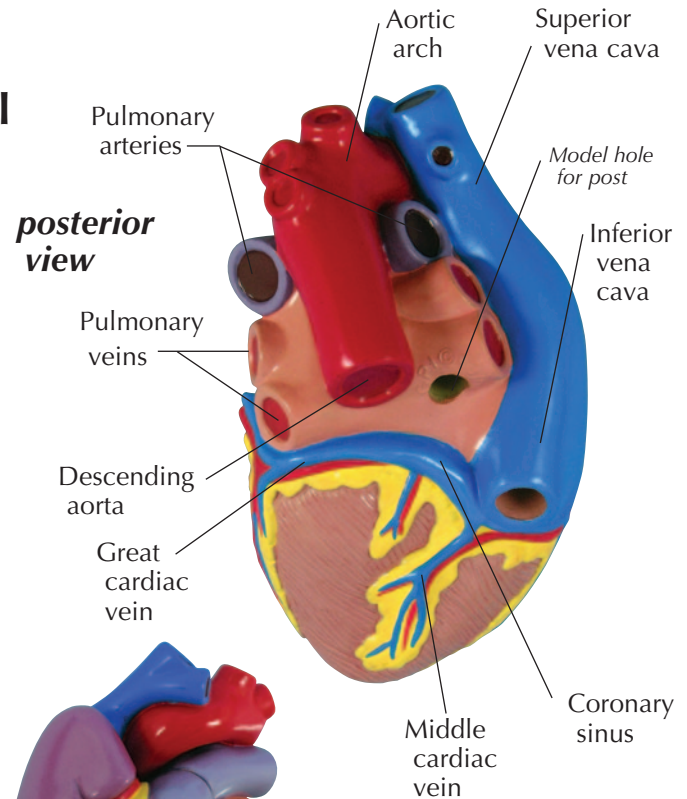
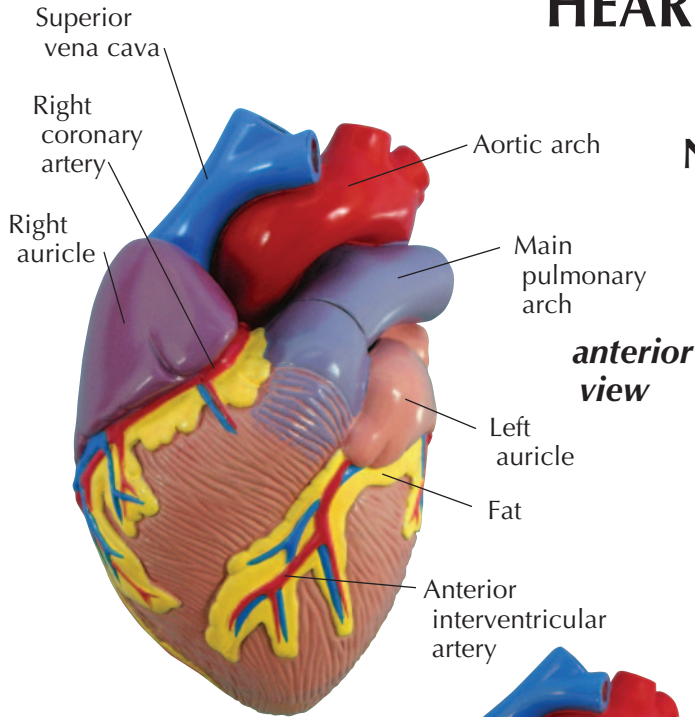
## Myocardial Infarction

Area of infarct (muscle wall thinner)

Thrombus

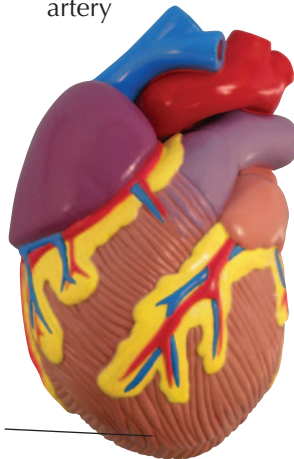
*interior view of posterior heart section*

# HEART DISEASE



## Congestive Heart Failure

Hypertrophic (thickened) myocardium



## Myocardial Infarction

Area of infarct

