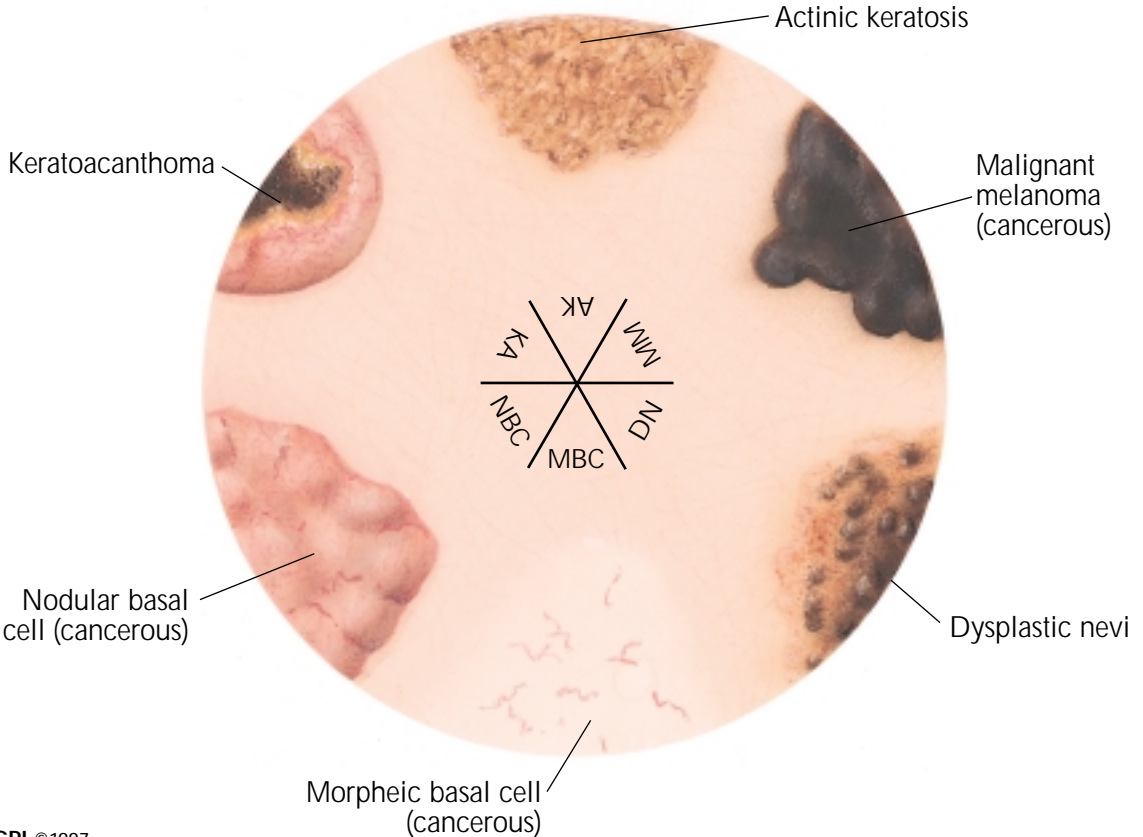
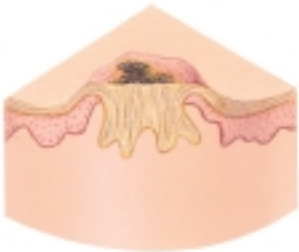

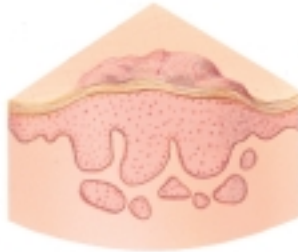# SKIN PATHOLOGY



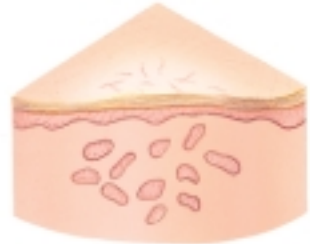# SKIN PATHOLOGY



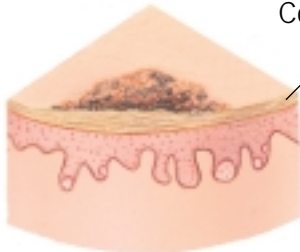Keratoacanthoma



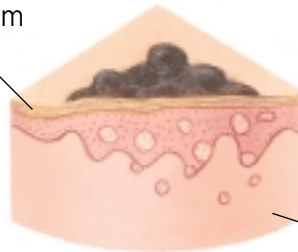
Nodular basal cell  
(cancerous)



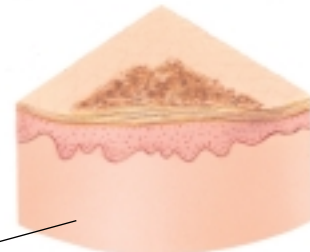
Morpheic basal cell  
(cancerous)



Dysplastic nevi



Malignant melanoma  
(cancerous)



Actinic keratosis

Corneum

Epidermis

Dermis