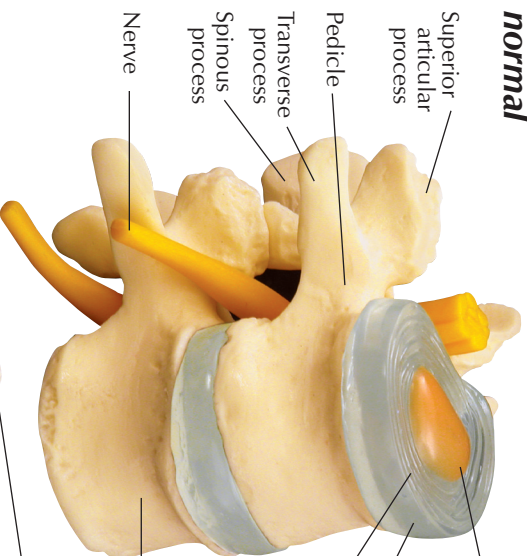
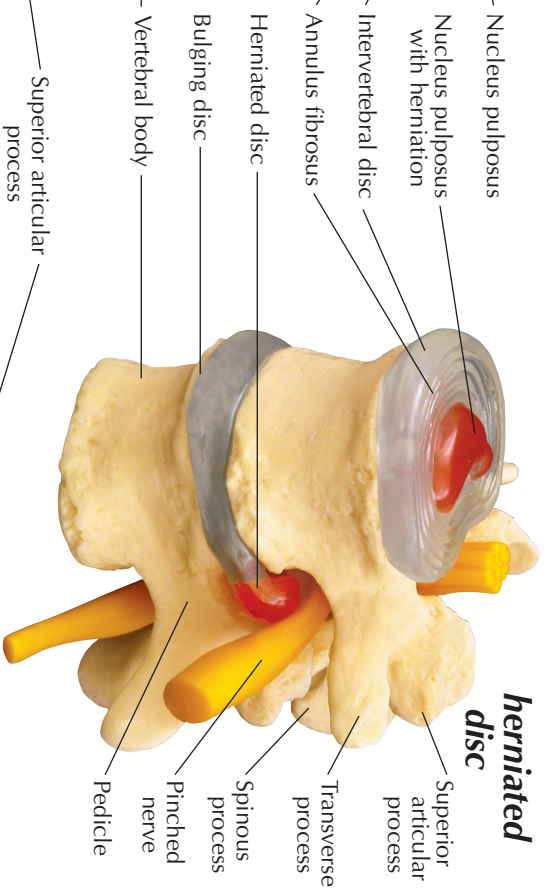


LUMBAR VERTEBRAE DEGENERATION

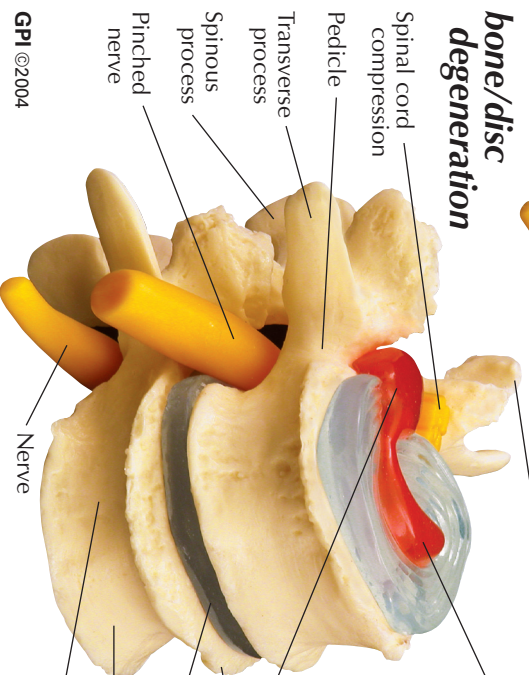
normal



herniated disc



bone/disc degeneration



advanced osteoporosis

